

### Keep Reading To...

- > Meet a racing champion that recovered from a leg fracture
- > Understand the realities of proper equine dentistry
  - > Tour the PBEC Imaging Department
- > Help keep your horses safe and calm during July 4th festivities

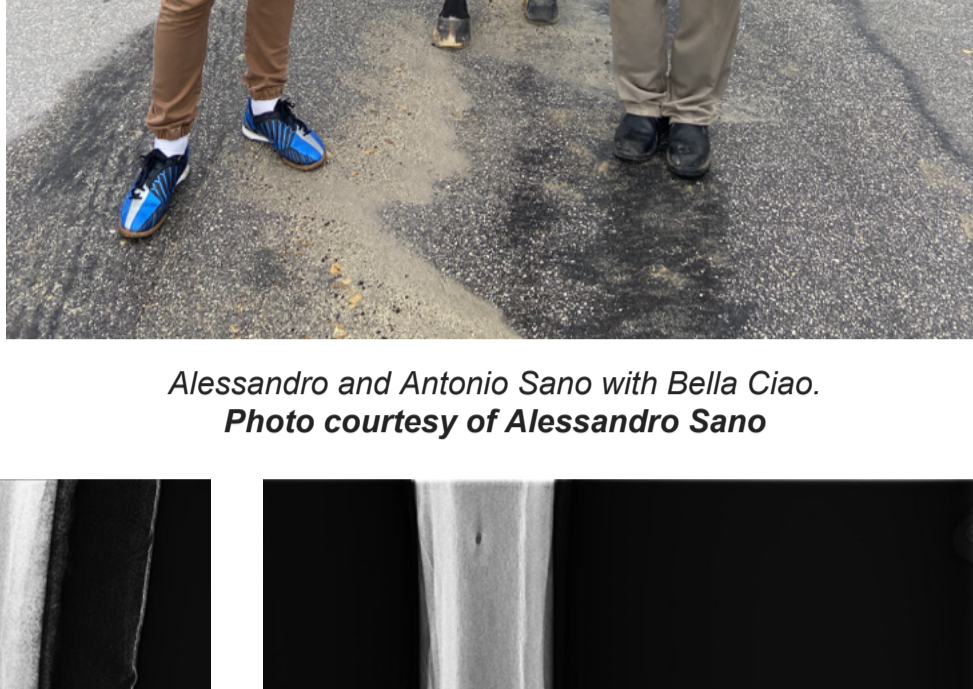## Bella Ciao: Back Out Front

Trainers Alessandro and Antonio Sano reviewed a daunting x-ray on the morning of April 19, 2019. Their three-year-old Thoroughbred filly Bella Ciao, owned by Cairoli Racing Stable and Magic Stables LLC, had just finished a breeze in 49 seconds flat when she pulled up from a fracture in her right front leg.

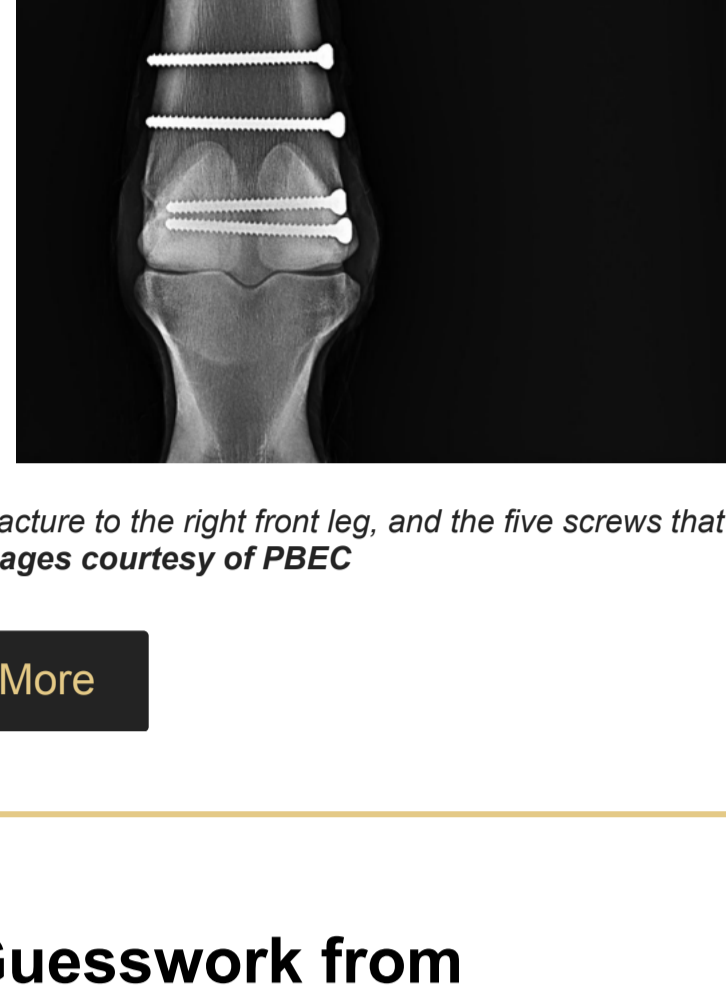
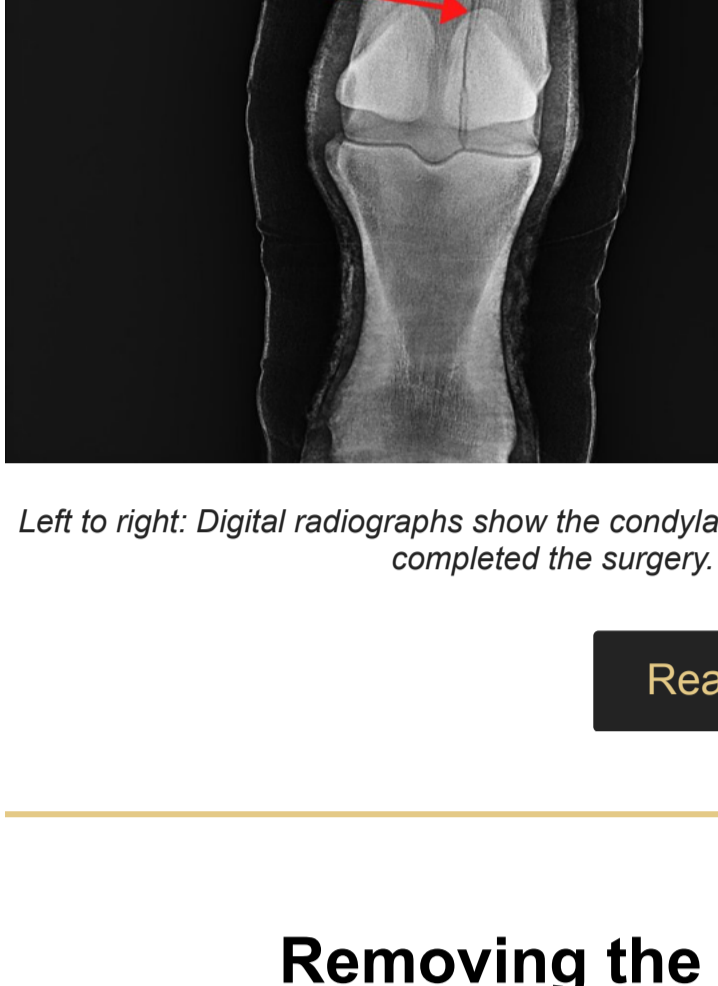
She exited the track at Gulfstream Park West, her home racecourse in Miami Gardens, FL, with her racing fate hanging in the balance.

"She is a tough filly with a lot of heart, and she walked herself back to the barn where we had x-rays taken," said Alessandro, who met with the track veterinarian right away to identify the problem. "When we saw it, we were nervous that she was headed to the breeding shed, and her career was over."

Alessandro and his father, however, were not willing to give up on their special filly. They entrust Palm Beach Equine Clinic's board-certified surgeon, Dr. Robert Brusie, with care of their entire string of racehorses, and quickly decided to send the x-rays for his review. Dr. Brusie quickly identified a condylar fracture and advised a surgical repair. Immediately after her diagnosis was confirmed, Bella Ciao made her way to the Hospital at Palm Beach Equine Clinic.



Alessandro and Antonio Sano with Bella Ciao. Photo courtesy of Alessandro Sano



Left to right: Digital radiographs show the condylar fracture to the right front leg, and the five screws that completed the surgery. Images courtesy of PBEC

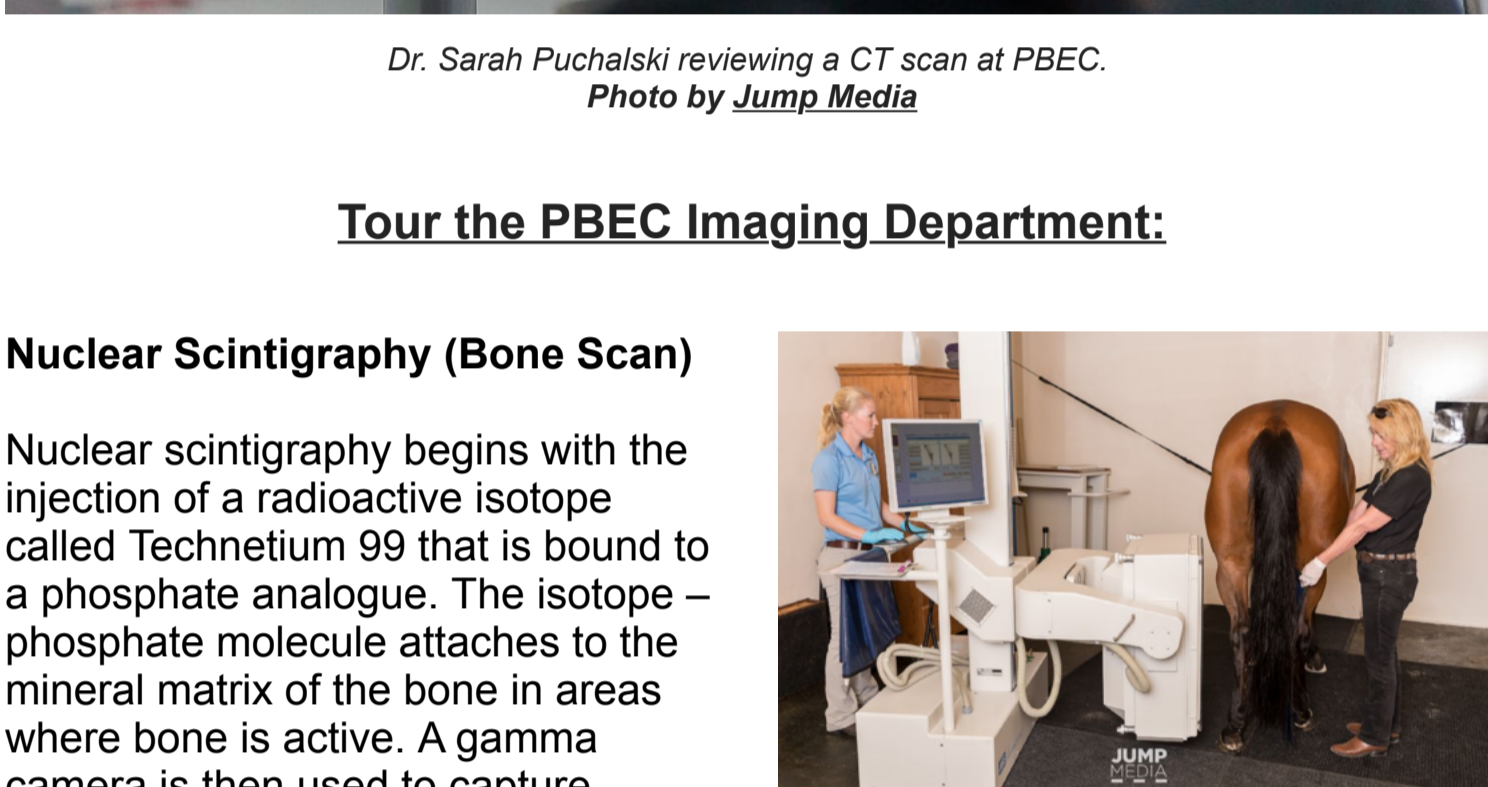
[Read More](#)

## Removing the Guesswork from Lameness Evaluations

### A Look at Palm Beach Equine Clinic's Advanced Imaging Technology

Palm Beach Equine Clinic takes pride in being a world-class facility for the diagnosis, treatment, and recovery of some of the industry's most valued sport horses, as well as backyard companions. A vital area of the Equine Hospital that helps veterinarians to diagnose subtle or acute lameness is the Advanced Imaging Department.

Producing thousands of scans a year across all modalities, the Palm Beach Equine Clinic Imaging Department offers an on-staff, board-certified radiologist, and equipment that elevates the effectiveness of lameness diagnostics. Lameness is no longer a guessing game as PBEC veterinarians have an arsenal of imaging technologies to capture inside the horse.



Dr. Sarah Puchalski reviewing a CT scan at PBEC. Photo by Jump Media

### Tour the PBEC Imaging Department:

#### Nuclear Scintigraphy (Bone Scan)

Nuclear scintigraphy begins with the injection of a radioactive isotope called Technetium 99 that is bound to a phosphate analogue. The isotope-phosphate molecule attaches to the mineral matrix of the bone in areas where bone is active. A gamma camera is then used to capture images of the skeletal anatomy. Points that "light up" on the image indicate increased metabolic activity as a possible site of injury.

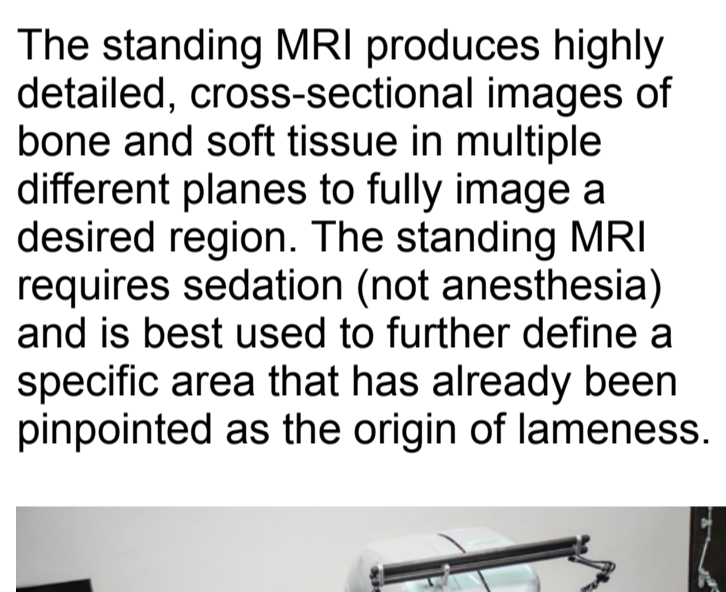


Photo by Jump Media

#### Standing Magnetic Resonance (MRI)



Photo by Jump Media

The standing MRI produces highly detailed, cross-sectional images of bone and soft tissue in multiple different planes to fully image a desired region. The standing MRI requires sedation (not anesthesia) and is best used to further define a specific area that has already been pinpointed as the origin of lameness.

#### Computed Tomography (CT)

CT produces highly detailed, cross-sectional images using x-ray beam technology. Current scanners allow veterinarians the opportunity to explore areas of a horse's body that were previously inaccessible. The machine produces images of a horse's neck and head and can be conducted while a horse is standing and under sedation.




Photo by Erin Gilmore

#### Endoscopy



Photo courtesy of PBE

An endoscope is an instrument that allows veterinarians to look inside the body by being inserted through a natural opening or incision. A tiny camera on the instrument allows an in-depth view of internal structures such as the upper and lower respiratory track, gastrointestinal and urinary tracts, as well as the cervix and uterus of mares.

#### Digital Radiography

Used routinely, radiographs are traditional x-rays that are made available within seconds for digital viewing and evaluation.



Photo by Erin Gilmore

#### Ultrasonography

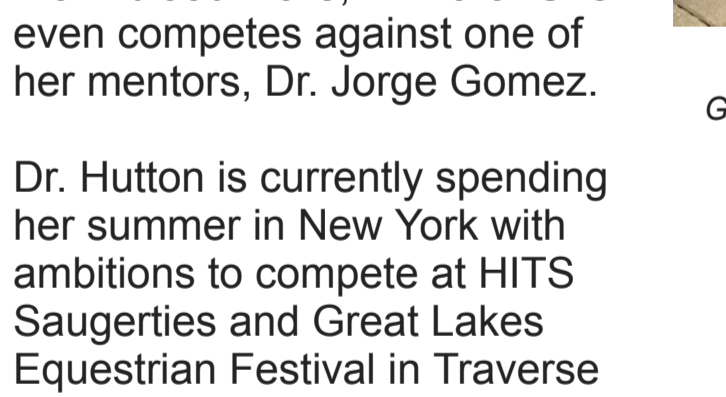


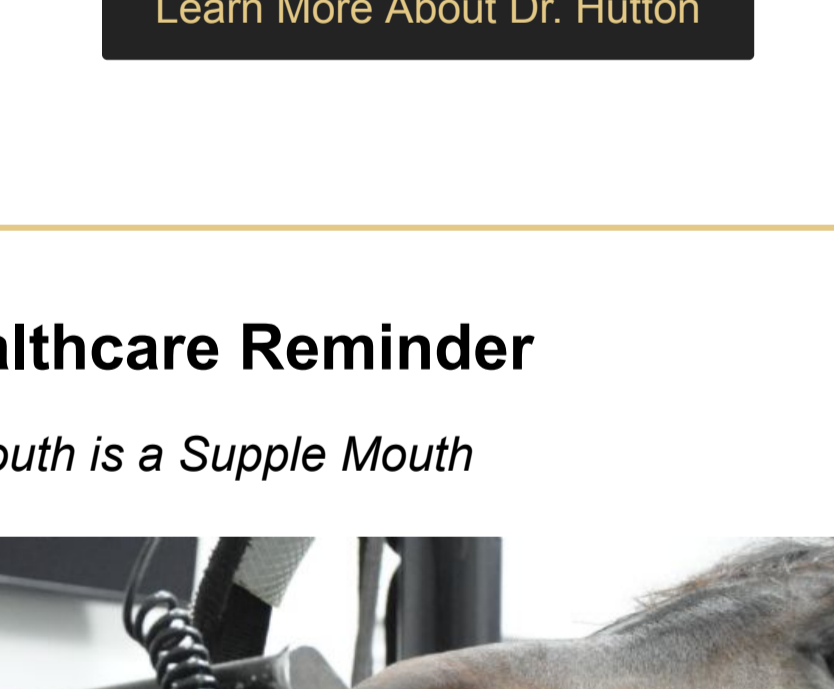
Photo courtesy of PBEC

An ultrasound machine generates excellent quality cross sectional images of soft tissues like tendons and ligaments. An ultrasound is non-invasive, usually does not require sedation, does not use radiation or require injecting radioactive isotopes, and provides real-time images.

[Read More](#)

## Meet The Team: Dr. Laura Hutton

Dr. Laura Hutton grew up immersed in equestrian culture in Enniskillen, Northern Ireland. She can't recall a time when she wasn't dreamily gazing at horses in a field or fantasizing about the day when she would pilot a show jumper in the competition ring. She knew at an early age that she wanted to be an equine veterinarian, and she stuck to that goal.



Dr. Laura Hutton after competing with Dr. Jorge Gomez at Palm Beach International Equestrian Center in Wellington, FL. Photo courtesy of Dr. Hutton

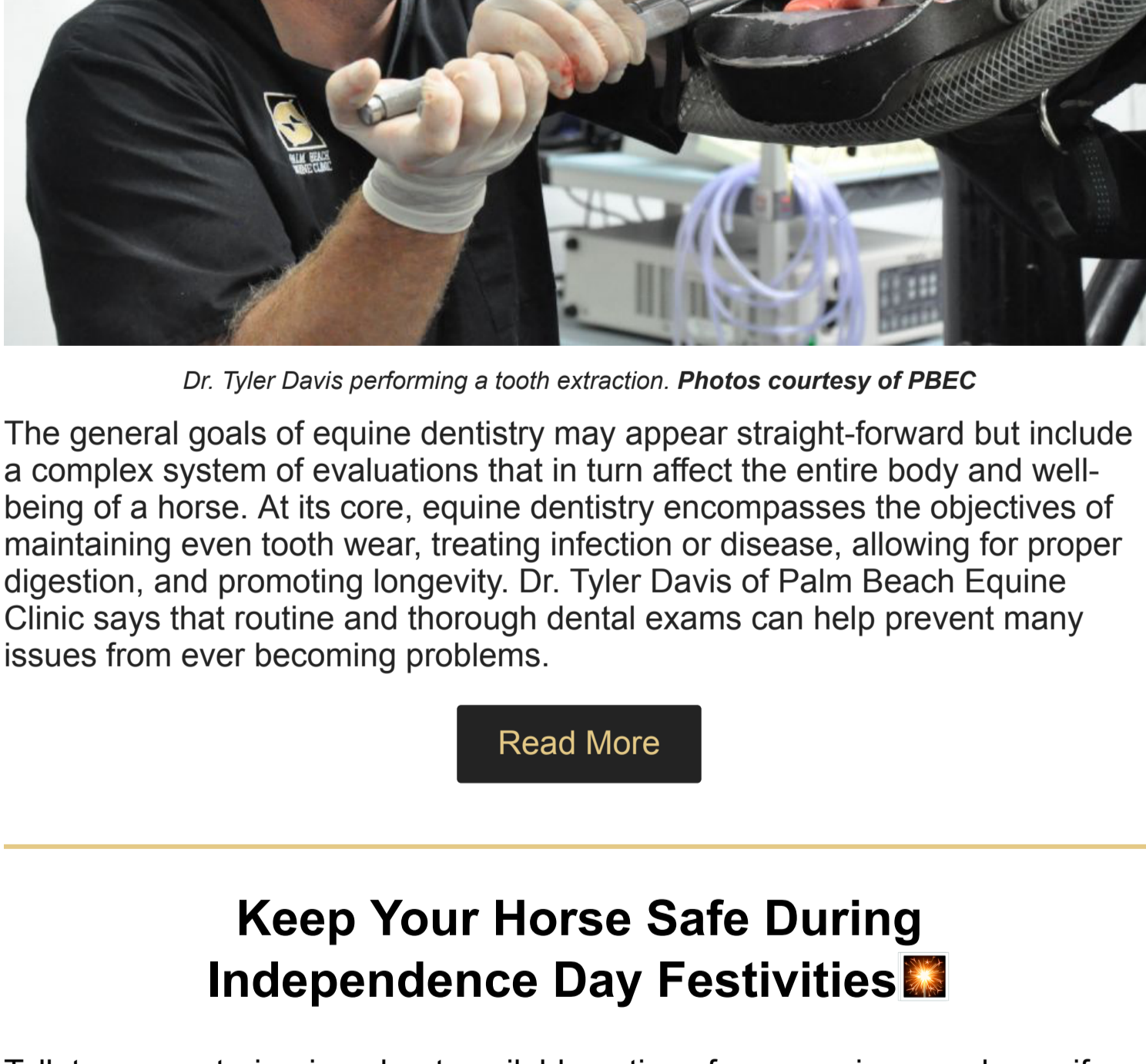When not caring for horses, Dr. Hutton can be spotted competing in the adult jumper ranks on her jet-black Dutch Warmblood mare, Brimara. She even competes, Dr. Jorge Gomez.

Dr. Hutton is currently spending her summer in New York with ambitions to compete at HITS Saugerties and Great Lakes Equestrian Festival in Traverse City, MI.

[Learn More About Dr. Hutton](#)

## Equine Healthcare Reminder

### A Healthy Mouth is a Supple Mouth



Dr. Tyler Davis performing a tooth extraction. Photos courtesy of PBEC


The general goals of equine dentistry may appear straightforward but include a complex system of evaluations that in turn affect the entire body and well-being of a horse. At its core, equine dentistry encompasses the objectives of maintaining even tooth wear, treating infection or disease, allowing for proper digestion, and promoting longevity. Dr. Tyler Davis of Palm Beach Equine Clinic says that routine and thorough dental exams can help prevent many issues from ever becoming problems.

[Read More](#)


## Keep Your Horse Safe During Independence Day Festivities

Talk to your veterinarian about the available options for managing your horse if you think they might not handle the sights and sounds of July 4th well.

The PBEC Pharmacy carries several options that your vet may advise:





◆ **Calming Cookies™ & Calming Powder™** made by **T.H.E. Equine Edge** contain a blend of natural vitamins, minerals and amino acids to improve your horse's general health and well being.



◆ **Zylkene Equine**, by **Barn Chats** by **Vetoquinol Equine**, contains a milk-derived protein that mimics a substance in mother's milk and might be responsible for the state of relaxation newborns experience after nursing.

Palm Beach Equine Clinic wishes its doctors and clients a safe July 4th weekend! The clinic offices will be closed on Saturday, however, the hospital and veterinarians are always available if your horse is in need. Call 561-793-1599 to speak with a veterinarian.



ABOUT THE CLINIC  
CLINIC SERVICES  
MEET THE VETERINARIANS  
CONTACT PALM BEACH EQUINE CLINIC

